

PATIENT PRESENTING CLINICAL SIGNS

Aggie Strisofsky

History: History of degenerative valve disease and CHF. Doing well currently. Current radiographs show cardiomegaly but no CHF.
Medication: furosemide 12.5 mg BID, benazepril 5 mg SID, pimobendan 3.75 mg BID.

SPECIES

Canine

ECHOCARDIOGRAPHIC FINDINGS

2D, M-mode, and Doppler study. This exam is compared to the one performed 12/28/20.

BREED

Maltese

There is mild left atrial dilation. The mitral valve leaflets are thickened and exhibit systolic prolapse. A moderate jet of eccentric mitral regurgitation is present. There is mild to moderate left ventricular dilation. Left ventricular systolic function is hyperdynamic. The aorta and aortic valve are normal. Right atrial and right ventricular dimensions are normal. The tricuspid valve is normal. The pulmonary artery and pulmonic valve are normal. No shunting lesions are visualized. No pericardial effusion or cardiac masses are seen.

SEX

FS

AGE

10 years

LA – 30.5 mm (prev. 30.4 mm)
LVIDd – 34.1 mm (prev. 33.9 mm)
LVIDs – 15.9 mm (prev. 19.1 mm)
FS – 53% (prev. 43.6%)
LVOT – 1.31 m/s (prev. 1.74 m/s)
RVOT – 1.31 m/s (prev. 1.15 m/s)

WEIGHT

14.5 lbs

ASSESSMENT/RECOMMENDATIONS

Degenerative mitral valve disease

INTERPRETED BY

Keith Blass, DVM, MS, DACVIM

This examination demonstrates no progression of Aggie’s mitral valve disease over the past year. Given the absence of progression, it’s a bit surprising to hear that Aggie experienced an episode of congestive heart failure, as the continued presence of only mild left atrial dilation suggests that her left atrial pressure is unlikely to be significantly elevated.

IMAGING PERFORMED BY

Rebekah Jakum, CVT ARDMS/RVT

No change in therapy is recommended based on this exam.

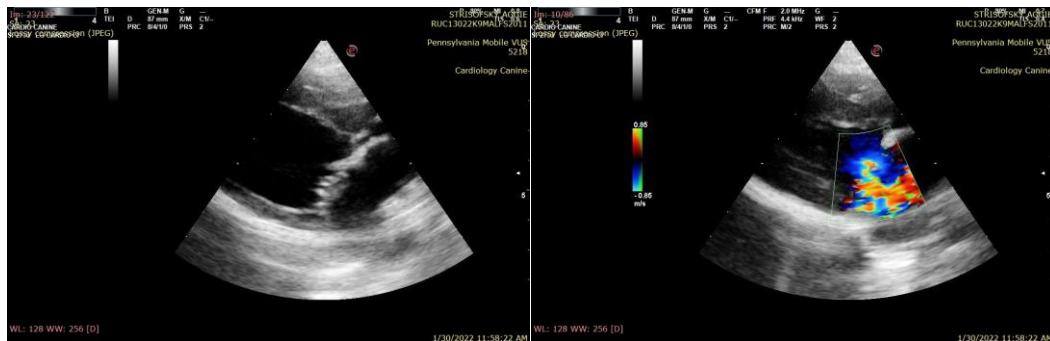A recheck echocardiogram is recommended in 9-12 months. Repeat radiographs are recommended if clinical signs compatible with congestive heart failure develop/recur.

HOSPITAL NAME

Rush VC

REFERRING VET

Dr. Urban

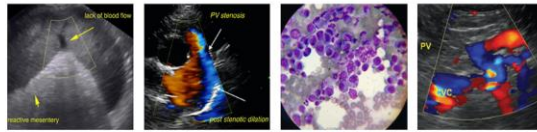


DATE

1.30.2022

The information and recommendations provided are based on the images presented by the referring veterinarian. No evaluation can be communicated regarding pathology that was not visible in the image/video clips provided.

Thank you for this referral. If the clinical or image interpretation does not parallel your findings or if I can be of any



PATIENT further assistance please contact me.

Aggie Strisofsky

SPECIES

Keith Blass, DVM, MS, DACVIM (Cardiology)
KeithBlass@gmail.com
631-804-5754

Canine

BREED

Maltese

SEX

FS

AGE

10 years

WEIGHT

14.5 lbs

INTERPRETED BY

Keith Blass, DVM,
MS, DACVIM

**IMAGING
PERFORMED BY**

Rebekah Jakum, CVT
ARDMS/RVT

HOSPITAL NAME

Rush VC

REFERRING VET

Dr. Urban

DATE

1.30.2022